

Nail Psoriasis

DIGA

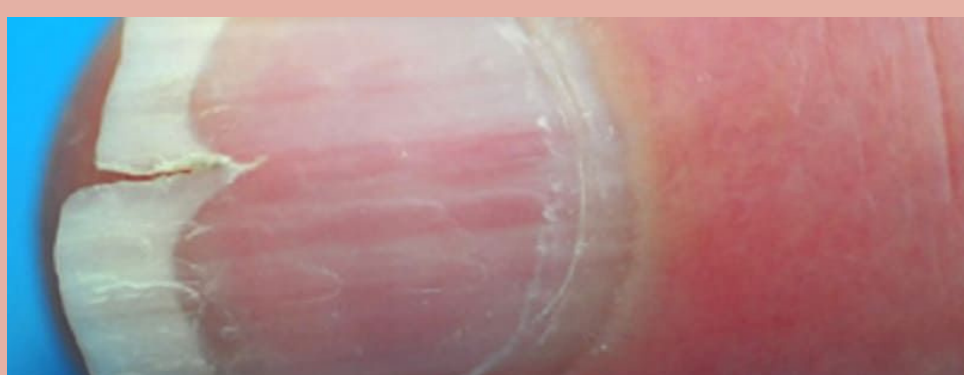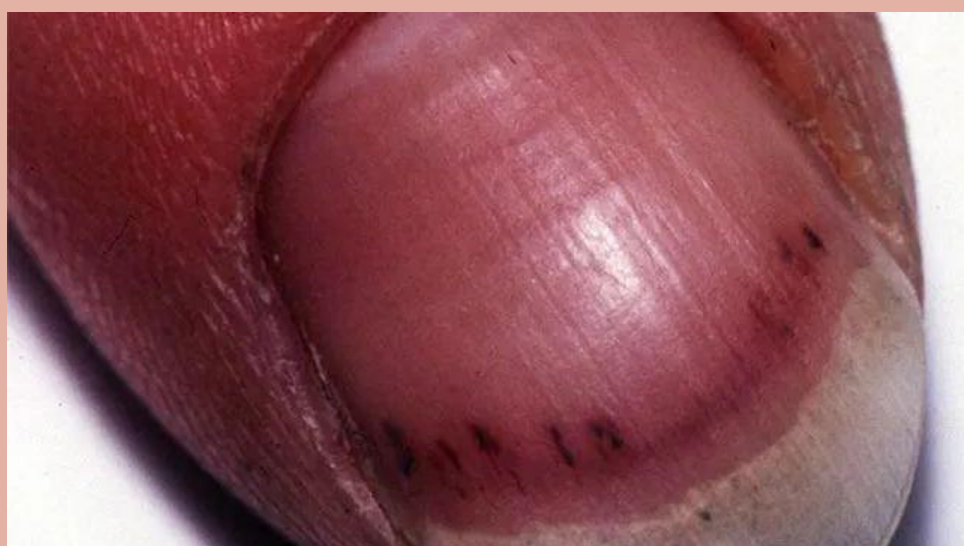EST. 2005

Overview

- Psoriasis is a chronic skin condition most commonly with cutaneous manifestations; however, nail involvement occurs in approximately 50% of cases.
- A wide variety of nail dystrophies are observed in nail psoriasis.

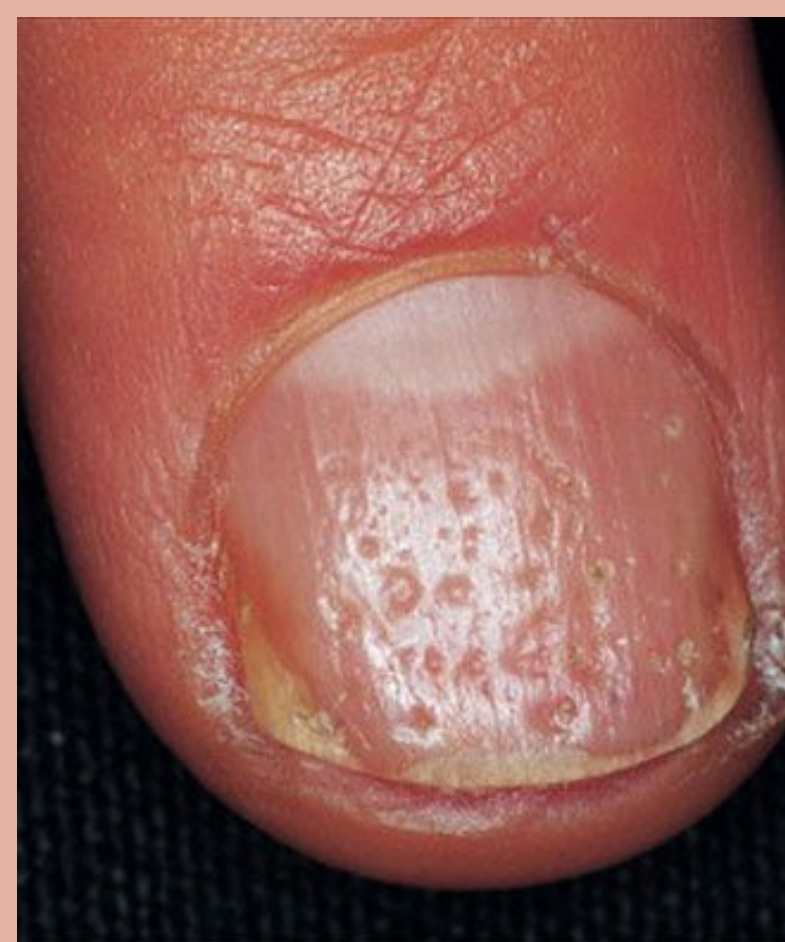Visual Description

- Nail dystrophies observed in psoriasis include nail pitting, loosening of the nail plate, discoloration and hemorrhages within the nail bed.



Common Locations

- Toenails or fingernails
 - Fingernails are more common
- The nail bed is most often affected

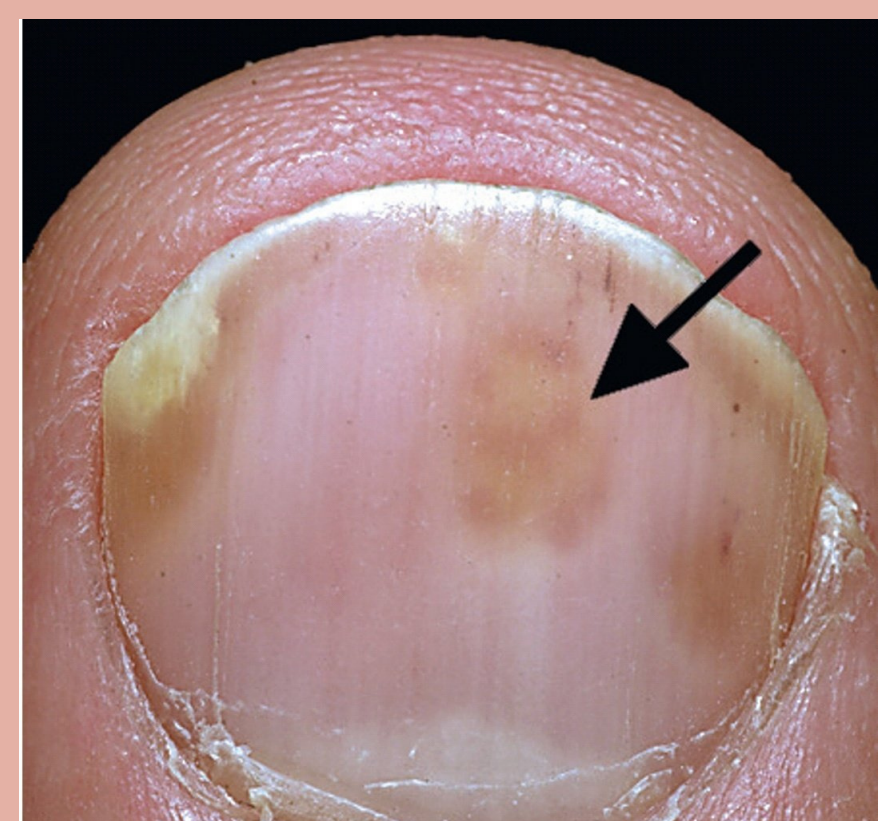


Symptoms/Course

- Nail pitting (depressions)
- Discoloration appearing as “oil drops” or “salmon-colored” spots
- Yellow-greasy toenails with a white-silvery presentation
- Longitudinal ridging, or splitting of the nails
- Leukonychia appears as white lines or dots
- Splinter hemorrhages include tiny blood spots under the nail that look like splinters

Treatment Options

- There is some evidence showing the efficacy of treatment with 5-fluorouracil, anthralin, tazarotene, and topical cyclosporine.
- Glucocorticosteroids and vitamin D3 analogs are the more commonly prescribed treatments for nail psoriasis.



References:

Jiaravuthisan MM, Sasseville D, Vender RB, Murphy F, Muhn CY. Psoriasis of the nail: anatomy, pathology, clinical presentation, and a review of the literature on therapy. J Am Acad Dermatol. 2007 Jul;57(1):1-27.