

THE DERM EXAM

Color + Primary Morphology + Secondary Morphology + Configuration + Distribution



PRIMARY MORPHOLOGY

| | < 1 cm | > 1 cm |
|----------------------------|--------------------|--------------------|
| Flat lesion | Macule | Patch |
| Raised lesion | Papule | Plaque |
| Raised fluid-filled lesion | Vesicle | Bullae |
| Raised pus-filled lesion | Pustule | Abscess |

| | |
|--|--|
| Nodule: Palpable mass in dermis/subcutis | |
| Wheal: transient elevation | |

SECONDARY MORPHOLOGY

| | |
|-----------------|--|
| Scale | |
| Crust | |
| Fissure | |
| Erosion | |
| Ulcer | |
| Atrophy | |
| Lichenification | |





CONFIGURATION

| | | | |
|-------------|--|------------|--|
| Clustered | | Retiform | |
| Annular | | Linear | |
| Serpiginous | | Dermatomal | |

DISTRIBUTION

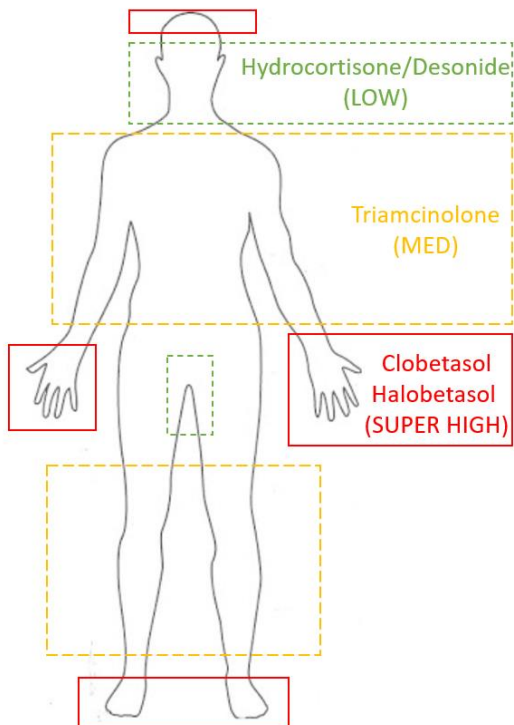
Disseminated vs localized
 Symmetric vs asymmetric
 Flexural vs extensor
 Acral (hands and feet)
 Mucosal
 Intertriginous

VEHICLES

| OINTMENT | CREAM | LOTION | SOLUTION |
|---|---|--|---|
| Strong potency Hydrating Low irritation risk | Moderate potency Moderate hydration Moderate irritation risk | Low potency Drying (2/2 alcohol) Moderate irritation risk | Low potency Drying (2/2 alcohol) High irritation risk |
|  |  |  |  |
| Use for dry, lichenified skin: ex. psoriasis, chronic eczema | Use for scaly, weepy skin: ex. acute eczema | Use for hair or face: ex. acne | Use for scalp: ex. psoriasis, seb derm |
| More occlusion More absorption | ← | | Less occlusion Less absorption |

TOPICAL STEROIDS

| Potency | Examples |
|-------------------|---------------------------------------|
| Super High | Clobetasol 0.05% Halobetasol 0.05% |
| High | Fluocinonide 0.05% |
| Medium | Triamcinolone 0.1% |
| Low | Hydrocortisone 2.5% Desonide 0.05% |



APPROXIMATING BSA

Patient's palm (excluding fingers) = 1% BSA
 1 fingertip unit = 0.5 g = 2% BSA (2 palms)
 30 mg = covers adult body x1

